PLASTIC RECONSTRUCTIVE & REGENERATIVE SURGERY

ONLINE FIRST 2025; JULY 28
DOI: 10.57604/PRRS-1313

USE OF DRAINAGE IN BREAST AUGMENTATION SURGERY: BENEFITS AND CLINICAL EVIDENCE FROM OUR EXPERIENCE

Michele Pio Grieco[1], Piera Iannelli[1,2], Stefano Lovero[1], Martina Iuliano[1], Flavia Aprea[1,2]

[1] Division of Plastic Surgery, IRCCS - Centro di Riferimento Oncologico della Basilicata, Rionero in Vulture, Italy; [2] Division of Plastic Surgery, AOU Federico II, Naples, Italy

Summary

The use of drains in plastic surgery remains a subject of debate, particularly in breast augmentation. Despite advancements in surgical techniques, postoperative complications such as hematomas and seromas, and their subsequent evolution, remain significant concerns, as they may even require reoperation. The use of breast drains during the procedure is a practice adopted by many surgeons to mitigate these risks. This article examines the benefits associated with the use of drains in breast augmentation, supported by clinical evidence and established surgical practices. In this retrospective study, the effectiveness of drainage in reducing postoperative complications, such as seromas and hematomas, and improving the postoperative course is analyzed. A total of 58 cases of breast augmentation were examined, divided into two groups: GROUP 1, patients with drainage placement, and GROUP 2, patients without drainage placement. Our study highlighted the usefulness of breast drain insertion in terms of reducing postoperative complications and improving postoperative management. A statistically significant increase in the incidence of seroma was observed in Group B (without drainage) when compared to Group A (with drainage), with rates of 25% and 15% respectively ($p = 0.03$) (Tab. I). In conclusion, the use of drains in breast augmentation not only benefits the immediate health and well-being of the patient but also contributes to ensuring a safer and faster recovery, reducing the likelihood of postoperative complications that could compromise the aesthetic and physical outcome of the procedure.

Key words: incision, breast augmentation, implants, drains, seromas

Received: May 7, 2025
Accepted: June 20, 2025

Correspondence
Flavia Aprea
E-mail: flavia.aprea@unina.it

How to cite this article: Grieco MP, Iannelli P, Lovero S, et al. Use of drainage in breast augmentation surgery: benefits and clinical evidence from our experience. PRRS Online First 2025;July 28. https://doi.org/10.57604/PRRS-1313

INTRODUCTION

Breast augmentation is one of the most commonly performed surgeries worldwide [1,2]. In aesthetic surgery, breast augmentation represents about 13.1% of all plastic surgery procedures [3]. In reconstructive surgery, breast implants are used in 80% of cases to restore volume and shape to the breast [4]. Despite advancements in surgical techniques, postoperative complications persist, including seromas, hematomas, and infections. The use

of drains is a strategy adopted to prevent the accumulation of fluids in the implant pocket [5], and consequently the formation of hematomas and seromas, as well as their progression to more severe complications. However, to date, their use remains controversial [5-7]. There are various types of drains, including suction drains (such as Jackson-Pratt drains) and passive drains. In recent years, scientific research has sought to optimize the use of these devices, assessing the benefits versus potential risks to improve aesthetic and functional outcomes for patients. This retrospective study aims to evaluate the benefits of intraoperative aspiration drain placement in breast augmentation and its influence on clinical outcomes.

MATERIALS AND METHODS

This study was conducted in accordance with the principles of the Declaration of Helsinki. The research protocol was reviewed and approved by the Institutional Review Board (IRB) of IRCCS-CROB, with approval number 17034.

All participants provided written informed consent prior to inclusion in the study.

The choice of surgical technique was based on the best site for creating the implant pocket, considering several parameters including: type of implant used, in terms of shape and volume, the patient's desired aesthetic result, and the "pinch test" [8], which measures the thickness of the subcutaneous tissue. Our study considered only patients undergoing breast augmentation with subglandular placement to standardize the sample. The patients were then divided into two groups:

- Group A with drainage placement;
- Group B without drainage.

Smoking patients were advised to refrain from smoking for two weeks before surgery and for three weeks afterward. Preoperative exams recommended by SIAARTI guidelines [9], including blood count, liver and kidney function tests, ECG, and coagulation, were performed, and only patients with normal coagulation values were included in the study protocol. Furthermore, preoperative assessment included the suspension of medications affecting coagulation (NSAIDs). All patients involved in the study signed informed consent for the procedure and inclusion in the study. The intervention was performed on a day-hospital basis under deep sedation, ensuring pain and perception control during the procedure. All patients underwent antibiotic prophylaxis according to guidelines [10], with intraoperative injection (within 30 minutes of skin incision of cefamezin 2g/IV) and continued at-home antibiotic therapy with Augmentin 1g every 8 hours for 5 days. Surgical maneuvers during the intervention followed strict sterility protocols [11]. The breast augmentation procedure was performed by the same surgical team for all patients, using two preferred access points: the inframammary fold access in patients with unfavorable anatomical conditions (such as an areolar diameter < 3 cm) [12] and the peri-areolar access in patients with an areolar diameter ≥ 3 cm. The inframammary approach involved a 5-7 cm incision at the fold [12,13], while the peri-areolar approach involved an incision at the junction between the skin and areola from 3 o'clock to 9 o'clock in the infra-areolar region [13-15]. After creating the implant pocket in the subglandular site, meticulous hemostasis was performed using electrocautery. Our surgical protocol included the disinfection of the implant pocket to reduce infection risk through the insertion of a first solution containing Betadine and hydrogen peroxide, left in place for 30 seconds before being aspirated, followed by a second wash with saline solution. Prior to implant insertion, a solution containing Betadine and Gentamicin was placed inside the implant's protective shell. Implants were inserted manually after glove replacement by the operators; during the procedures, all women received POLYTECH® latest-generation implants, whose external shell is made of a silicone elastomer that provides high resistance to chemical and mechanical stress, containing a silicone gel designed for long-term implants [16]. Round, microtextured implants were inserted in all patients, as literature has shown that microtextured implants are associated with fewer postoperative complications [17]. After implant placement, Redon drains, a type of vacuum drain that allows for constant fluid aspiration, were inserted in the patients who required it. The drainage was inserted at the junction point between the extended inframammary fold and the anterior axillary line, as this site provides an optimal balance between aesthetic results and postoperative management [18]. The drains were fixed to the skin with 2-0 silk sutures to prevent slippage. At the end of the procedure, all patients were dressed in a compression garment and instructed to wear an elastic bra for at least one month postoperatively, extending this period to three months when possible, as this has been shown to reduce postoperative edema in breast procedures [19]. The drainage site was dressed with gauze soaked in quaternary ammonium salts as recommended by the literature [20]. For patients with drains, the correct timing for removal was determined based on the volume and characteristics of the drainage fluid over the first 24 hours [21,22]. The drain was removed when the fluid volume in the drainage was ≤ 30 ml, and the fluid had a serous or serosanguineous appearance. Patients in the drainage group were instructed on managing the drains, and they were provided with a clinical diary to

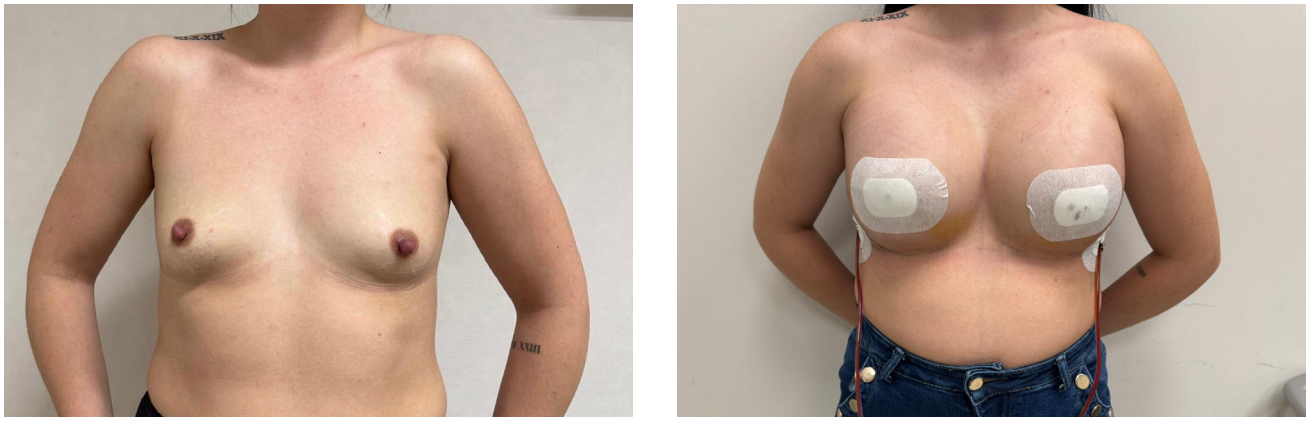

Figure 1. Patient group A with emiperiareolar incision and subglandular implant.

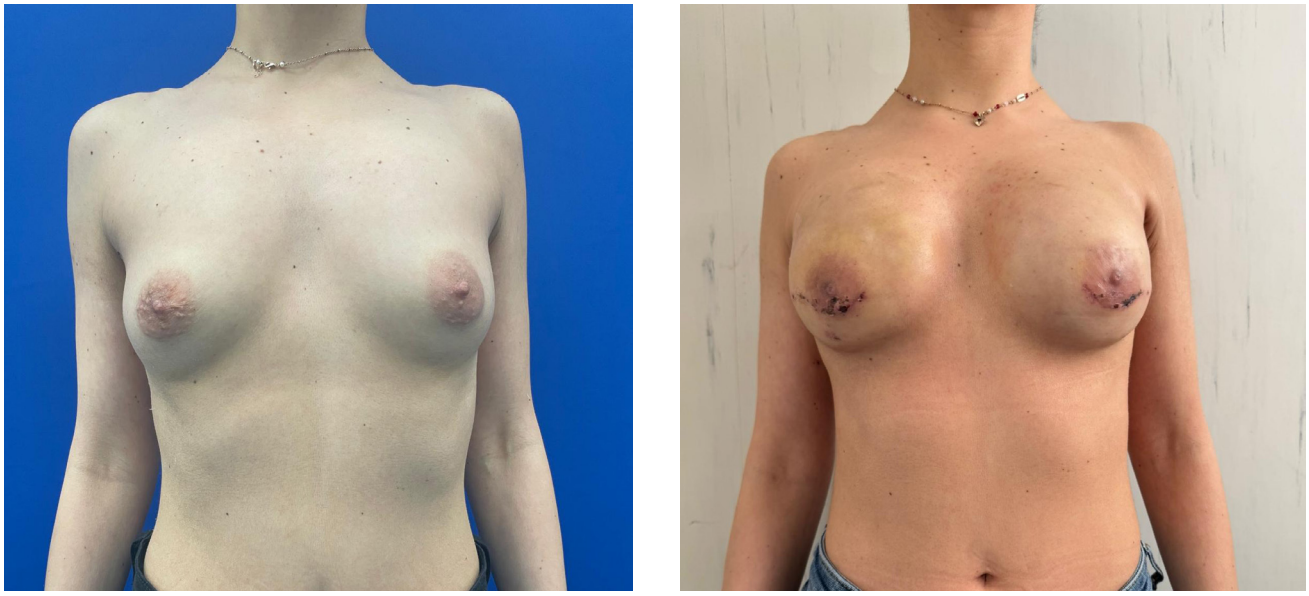

Figure 2. Patient group B with emiperiareolar incision and subglandular implant.

record the volume and appearance of the drained fluid every 24 hours. Both groups were scheduled for a follow-up visit at 72 hours to determine whether drainage should be removed and to check for any complications in the non-drainage group. At discharge, all patients received a pain management protocol, which included paracetamol 1000 mg every 8 hours for 5 days, followed by paracetamol as needed.

The analyzed variables included:

1 Incidence of seromas and hematomas;
2 Postoperative pain (Visual Analog Scale, VAS) [23];
3 Need for subsequent percutaneous drainage;
4 Recovery time and return to normal activities;
5 Infection rate.

Follow-up was performed at 3 days, 30 days, 6 months, and 1 year post-surgery.

RESULTS AND STATISTICAL ANALYSIS

The study involved 83 patients who underwent breast augmentation between 2020 and 2024. Of the 83 patients, 70% (58 women) received subglandular placement, while 30% (25 women) received submuscular placement. The patients involved in the study were aged between 19 and 55 years (mean age 39 years) with a BMI ranging from 18.5 to 26 (mean 24.5) (Tab. II). Our

Table I. Incidence of postoperative complications.

	Group A	Group B	p value
Infection	1 (3,4%)	1 (3,6%)	1,00
Hematoma	2 (6,7%)	4 (15%)	0,60
Seroma	4 (15%)	10 (25%)	0,03

Table III. Postoperative pain (Visual Analog Scale, VAS).

	1st-2nd days	3rd-4th days	5th days
GROUP1	7	5	3
GROUP2	6	4	3

study considered only patients undergoing breast augmentation with subglandular placement divided into two groups, Group A with drainage placement 30 patients, Group B without drainage 28 patients. In Group A, only 15% of patients (4 patients) developed seromas, a significantly lower percentage compared to 25% in Group B (10 patients) (Tab. I). For patients in Group A who developed seromas, drainage was continued until clinical and ultrasonographic resolution of the fluid collection. In contrast, for the 2 patients in Group B, manual drainage was required to remove the seroma, and in 50% of cases, reoperation was necessary. This highlights the more complex management of seromas in Group B compared to Group A, as well as the need for reoperation in some patients in the no-drainage group, at which point a drain was inserted. The frequency of hematomas was also lower in Group A (7%) compared to Group B (15%) (Tab. I). Regarding postoperative pain, assessment using the VAS scale showed higher pain scores in Group A during the first three days compared to Group B. Specifically, in Group A, the mean pain score on days 1 and 2 was 7, and on days 3 and 4 it was 5. In Group B, patients reported a pain score of 6 on days 1 and 2, and 4 on days 3 and 4. However, from day 5 onward, the differences between the two groups disappeared, indicating that the postoperative course was similar in both groups in the medium term (Tab. III). Finally, no significant differences emerged regarding infection rates between the two groups, with an infection rate of 4% in both (Tab. I). Statistical analysis demonstrated good homogeneity between the two groups with regard to baseline characteristics (Tab. III), comorbidities (Tab. IV), and main risk factors, as detailed below. The mean age was similar in both groups (Group A: 39.2 years; Group B: 38.7 years; $p = 0.498$) (Tab. II). Likewise, there was no significant difference in body mass index (BMI) between the groups (24.54 *vs* 24.7; $p = 0.223$) (Tab. II). The proportion of smokers was comparable (33% in Group A vs 32% in Group B; $p = 0.90$) (Tab. II).

Table II. General characteristics of group.

	Group A (n = 30)	Group B (n = 28)	p value
Average age	39,2	38,7	0,498
BMI	24,54	24,7	0,223
Smokers	10 (33%)	9 (32%)	0,90
Surgical access	IMF 16 (53%) / PA 14 (47%)	IMF 13 (54%) / PA 15 (46%)	0,92

Table IV. Comorbidity.

Comorbidity	Group A (n = 30)	Group B (n = 28)	p value
Hypertension	2 (7%)	3 (11%)	0,61
DM type 2	1 (3%)	1 (3,5%)	0,92
Drug allergies	3 (10%)	2 (7%)	0,68
Previous surgical interventions	5 (17%)	6 (21%)	0,70
Preoperative intake of FANS	0	0	-
Coagulopathies	0 (esclusi)	0 (esclusi)	-

No statistically significant difference was observed in the type of surgical access used (IMF *vs* PA; $p = 0.92$) (Tab. II). No significant differences emerged between the two groups regarding the presence of hypertension (7% *vs* 11%; $p = 0.61$) (Tab. IV), type 2 diabetes mellitus (3% *vs* 3.5%; $p = 0.92$) (Tab. IV), drug allergies (10% vs 7%; $p = 0.68$) (Tab. IV), or previous surgical procedures (17% vs 21%; $p = 0.70$) (Tab. IV). No patients used NSAIDs preoperatively, and all subjects with known coagulopathies were excluded from the study (Tab. IV). The incidence of postoperative infection was identical in both groups (1 case each; $p = 1.00$), as was the incidence of hematoma (6.7% in Group A *vs* 15% in Group B; $p = 0.60$), with no statistically significant difference. However, a statistically significant difference was observed in the incidence of seroma, which was higher in Group B (without drainage) compared to Group A (25% *vs* 15%; $p = 0.03$) (Tab. I).

DISCUSSION

As stated at the beginning of our study, primary breast augmentation is one of the most performed plastic surgery procedures worldwide [1]. Consequently, given the high number of surgeries performed annually, complications are not negligible as they occur relatively frequently [2]. The majority of complications arise from the accumulation of postoperative fluids, such as blood and serum, within the implant pocket [6]. Surgical drains are

devices used to remove fluid accumulations, such as blood and serum, from the operated area [7,14,24]. Indeed, in breast augmentation, the insertion of implants creates a potential space where postoperative fluids can accumulate [25]. The accumulation of these fluids can lead to complications such as hematomas and seromas [7]. The use of drains aims to prevent these complications and, consequently, to avoid their unfavorable progression, facilitating the postoperative course and making it safer and more comfortable for the patient [25,26]. The use of drains in breast augmentation is a practice that, unfortunately, in our opinion, is often underestimated and considered non-determinant in improving the postoperative course and reducing complications [21,24,27]. However, as demonstrated in our study, the benefits are numerous and crucial for a smooth recovery free from complications. One of the most evident benefits of drains is their ability to prevent the formation of hematomas and seromas. These accumulations of blood or fluid, if not controlled, can severely compromise the healing process, both aesthetically and physically [12]. Drains, in fact, act as true "drainage systems," removing excess fluids from the operated area, preventing local pressure, and limiting the formation of these bothersome collections. In particular, in the first postoperative days, when fluid production is higher, drains serve as a fundamental barrier against the risk of complications [28]. Another important aspect is the ability of drains to act as a monitoring tool. The quantity and nature of the fluids being drained provide the surgeon with crucial information regarding the wound status and the potential onset of active bleeding. An excessive flow of blood can act as an early warning sign, allowing for timely intervention [22]. This continuous monitoring, though seemingly simple, is one of the most useful practices to ensure that potential complications are identified early and treated promptly. The accumulation of fluids exerts direct pressure on the sutures and surrounding tissues, increasing the risk of wound dehiscence and delaying the healing process [29,30]. Drains, by removing these fluids, reduce pressure and promote faster and safer healing. Postoperative recovery can be painful, and the presence of excess fluid only exacerbates the discomfort. In this context, drains play an important role, not only in preventing complications but also in improving the patient's comfort. By reducing swelling and pain, drains allow the patient to face the more difficult days of recovery with greater peace of mind. Finally, a crucial aspect regarding infection prevention must be addressed. Fluids accumulating in the operated area, if not drained, can create an ideal environment for bacterial proliferation. In such a context, infection is a complication that can seriously compromise the aesthetic outcome and the patient's health. Drains, by keeping the area free from fluid collections, play a preventive role, reducing the risk of bacteria finding fertile ground to develop and infect the operated area. It must be noted that some studies associate the presence of drains with a higher risk of infection [31], but our experience contradicts this thesis, as no significant differences in infection rates were observed between the two groups in the study. Some studies suggest that patients who do not have initial drains have an increased risk of seromas and hematomas and highlight the difficulty of resorting to percutaneous drainage in patients with implants due to the risk of implant rupture and infection onset, necessitating percutaneous drainage in the following days [29,30]. This underscores how the preventive use of drains can greatly simplify the recovery process and reduce the risk of complications. To date, many studies in the literature find no benefit in the use of drains in primary breast augmentation [14,24]. In contrast, our experience finds that the application of drains is a valuable tool for better patient management in primary breast augmentation procedures.

CONCLUSIONS

In conclusion, at the end of our study, the use of drains in breast augmentation has proven to be a crucial choice for ensuring a smooth and complication-free postoperative recovery. These devices play a pivotal role not only in preventing the formation of hematomas and seromas but also in continuously monitoring bleeding, providing the surgeon with an effective tool to intervene promptly if necessary. Our experience suggests that the absence of initial drainage complicates fluid management, increasing the need for percutaneous drainage at a later stage, further emphasizing the importance of active prevention. Statistical analysis from our study supports the use of surgical drains in breast augmentation as an effective strategy to reduce postoperative complications, particularly the incidence of seroma. While most variables showed no significant difference between groups, the significantly lower seroma rate in patients with drains ($p = 0.03$) underscores their preventive value. These findings suggest that routine drain placement may enhance surgical safety and improve patient outcomes by minimizing fluid-related complications. Drains not only improve the safety of the surgical procedure but also promote a more comfortable and less stressful postoperative recovery. In conclusion, the use of drains in breast augmentation not only benefits the immediate health and well-being of the patient but also contributes to ensuring a safer and faster recovery, reducing the likelihood of postoperative complications that could compromise the aesthetic and physical outcome of the procedure.

Conflict of interest statement
The authors declare no conflict of interest.

Funding
This research did not receive any specific grant from funding agencies in the public, commercial, or not-for-profit sectors.

Author contributions
MPG: study design, collection of data, data analysis/interpretation; PI: writing of the manuscript; SL: collection of data, data analysis/interpretation; FA: study design, collection of data, data analysis/interpretation, writing of the manuscript.

Abbreviations
A: conceived and designed the analysis
D: collected the data
DT: contributed data or analysis tool
S: performed the analysis
W: wrote the paper

Ethical consideration
This study was conducted in accordance with the principles of the Declaration of Helsinki. The research protocol was reviewed and approved by the Institutional Review Board (IRB) of IRCCS-CROB, with approval number 17034.
All participants provided written informed consent prior to inclusion in the study.

References
1 Hidalgo DA, Spector JA. Breast augmentation. Plast Reconstr Surg 2014;133:E567-E583. https://doi.org/10.1097/PRS.0000000000000033
2 Fardo D, Sequeira Campos MB, Pensler JM. Breast augmentation 2023;Jul 18. In: StatPearls [Internet]. Treasure Island (FL): StatPearls Publishing 2025.
3 International Society of Aesthetic Plastic Surgery. ISAPS International Survey on Aesthetic/Cosmetic Procedures performed in 2021.
4 American Society of Plastic Surgeons. Plastic Surgery Statistics Report. ASPS National Clearinghouse of Plastic Surgery Procedural Statistics.
5 Atlas of Aeshtetic Breast Surgery, Dennis C. Hammond.
6 Charles-de-Sá L, Gontijo-de-Amorim NF, Rossi JK, et al. Drainage on augmentation mammoplasty: does it work? J Plast Reconstr Aesthet Surg 2021;74:1093-1100. https://doi.org/10.1016/j.bjps.2020.10.059
7 Spear SL. The role of drains in breast surgery. A systematic review. J Plast Reconstr Aesthet Surg 2017;73:651-662. https://doi.org/10.1016/j.bjps.2019.11.019
8 Khan UD. Selection of breast pocket using the pinch test in augmentation mammoplasty: can it be relied on in the long term? Aesthetic Plast Surg 2009;33:780-781. https://doi.org/10.1007/s00266-009-9315-2
9 De Hert S, Staender S, Fritsch G, et al. Pre-operative evaluation of adults undergoing elective noncardiac surgery: Updated guideline from the European Society of Anaesthesiology. Eur J Anaesthesiol 2018;35:407-465.
10 Krizek Tj, Glottileb Lj, Koss N, et al. The use of prophylactic anticìbacterial in plastic surgery. Plast Reconstr Surg 1985;76:953-963. https://doi.org/10.1097/00006534-198512000-00032
11 Ministero Della Salute, Raccomandazioni per la sicurezza in sala operatoria.
12 Klaus L, ed. Plastic surgery of the breast, third edition, Chapter 1: breast augmentation. Berlin Heidelberg: Springler 2005, p. 30.
13 Austin RE, Saheb-Al-Zamani M, Lista F, et al. Periareolar augmentation-mastopexy. Aesthet Surg J 2019;39:953-965. https://doi.org/10.1093/asj/sjz128
14 Torresetti M, Zavalloni Y, Peltristo B, et al. A Shakespearean Dilemma in breast augmentation: to use drains or not? A systematic review: drains in breast augmentation. Aesthetic Plast Surg 2022;46:1553-1566. https://doi.org/10.1007/s00266-021-02693-7
15 Mang WL. Manual of aesthetic surgery. Chapter 1: breast augmentation. Berlin Heidelberg: Springler 2005, p. 152.
16 Protesi mammarie. POLYTECH Health & Aesthetics.
17 Han S, Kim R, Kim TS, et al. A preliminary retrospective study to assess the short-term safety of traditional smooth or microtextured silicone gel-filled breast implants in Korea. Medicina (Kaunas) 2021;57:1370. https://doi.org/10.3390/medicina57121370
18 Nishioka H, Yasunaga Y, Yanagisawa D, et al. Where do you insert a drain tube during breast reconstruction? Surg Today 2020;50:1626-1632. https://doi.org/10.1007/s00595-020-02043-1
19 Johansson K, Jönsson C, Björk-Eriksson T. Compression treatment of breast edema: a randomized controlled pilot study. Lymphat Res Biol 2020;18:129-135. https://doi.org/10.1089/lrb.2018.0064
20 Strong AL, Wolfe ET, Shank N, et al. Gauze impregnated with quaternary ammonium salt reduces bacterial colonization of surgical drains after breast reconstruction. Ann Plast Surg 2018;80(6S Suppl. 6):S426-S430. https://doi.org/10.1097/SAP.0000000000001420
21 Woo KJ, Paik JM, Mun GH, et al. Analysis of factors influencing drain amount, time to drain removal, and seroma formation in patients undergoing immediate expander-implant breast reconstruction. J Plast Surg Hand Surg 2018;52:53-59. https://doi.org/10.1080/2000656X.2017.1330208
22 Bendavid R, Kux M. Seromas. In: Bendavid R, Abrahamson J, Arregui ME, eds. Abdominal wall hernias. Principles and management. Springer 2001:753-756.
23 Sung YT, Wu JS. The Visual Analogue Scale for Rating, Ranking and Paired-Comparison (VAS-RRP): a new technique for psychological measurement. Behav Res Methods 2018;50:1694-1715. https://doi.org/10.3758/s13428-018-1041-8
24 Montemurro P, Gupta T. It is time to resolve the dilemma

and move away from using drains in primary breast augmentation. Aesthet Surg J Open Forum 2023;5:ojad048. https://doi.org/10.1093/asjof/ojad048

[25] Durai R, Mownah A, Ng PC. Use of drains in surgery: a review. J Perioper Pract 2009;19:180-186. https://doi.org/10.1177/175045890901900603

[26] Rosique RG et al. Seroma formation after breast surgery: prevention and management. Ann Plast Surg 2020.https://doi.org/10.4048/jbc.2012.15.4.373

[27] Ollech CJ, Block LM, Afifi AM, et al. Effect of drain placement on infection, seroma, and return to operating room in expander-based breast reconstruction. Ann Plast Surg 2017;79:536-540. https://doi.org/10.1097/SAP.0000000000001174

[28] Jordan SW, Khavanin N, Kim JYS. Seroma in prosthetic breast reconstruction. Plast Reconstr Surg 2016;137:1104-1116. https://doi.org/10.1097/01.prs.0000481102.24444.72 WUWHSSIconsensus_IT_Web.pdf

[29] Campbell RM, Dufresne RG. Dehiscence and necrosis. In: Gloster HM, ed. Complications in cutaneous surgery. New York: Springer 2008, pp. 77-86.

[30] Mujagic E, Zeindler J, Coslovsky M, et al. The association of surgical drains with surgical site infections – A prospective observational study. Am J Surg 2019;217:17-23. https://doi.org/10.1016/j.amjsurg.2018.06.015